


# Medical Practice and Reviews

Volume 5 Number 2 August 2014

ISSN 1996-0816



## ABOUT JMPR

**Medical Practice and Reviews (MPR)** is published monthly (one volume per year) by Academic Journals.

**Medical Practice and Reviews (MPR)** is an open access journal that provides rapid publication (monthly) of articles in all areas of the subject such as medical education, medical research, Neuroscience, Immunology etc. The Journal welcomes the submission of manuscripts that meet the general criteria of significance and scientific excellence. Papers will be published shortly after acceptance. All articles published in MPR are peer-reviewed.

## Submission of Manuscript

Submit manuscripts as e-mail attachment to the Editorial Office at: [mpr@academicjournals.org](mailto:mpr@academicjournals.org). A manuscript number will be mailed to the corresponding author shortly after submission.

Medical Practice and Reviews (MPR) will only accept manuscripts submitted as e-mail attachments.

Please read the **Instructions for Authors** before submitting your manuscript. The manuscript files should be given the last name of the first author.

## Editors

**Dr. Imtiaz Ahmed Wani**

*Shodi Gali ,Amira Kadal , Srinagar,  
India*

**Dr. M Abbasi**

*Tehran university of Medical Science,  
Tehran,  
Iran.*

**Dr. Theodoros Xanthos**

*University of Athens  
Medical School  
Greece.*

**Dr. Chih Ming Lin**

*No. 10, 3F-5 ( Quant Tu da quao),  
alley 33, Ming-Tzu road,  
Chuwei, Taipei county,  
Taiwan*

**Dr. Ahmed Rady**

*P.O.BOX 518  
Alexandria 21511  
Egypt.*

**Fees and Charges:** Authors are required to pay a \$600 handling fee. Publication of an article in the Medical Practice and Reviews is not contingent upon the author's ability to pay the charges. Neither is acceptance to pay the handling fee a guarantee that the paper will be accepted for publication. Authors may still request (in advance) that the editorial office waive some of the handling fee under special circumstances.

**Copyright: © 2014, Academic Journals.**

All rights Reserved. In accessing this journal, you agree that you will access the contents for your own personal use but not for any commercial use. Any use and or copies of this Journal in whole or in part must include the customary bibliographic citation, including author attribution, date and article title.

Submission of a manuscript implies: that the work described has not been published before (except in the form of an abstract or as part of a published lecture, or thesis) that it is not under consideration for publication elsewhere; that if and when the manuscript is accepted for publication, the authors agree to automatic transfer of the copyright to the publisher.

#### **Disclaimer of Warranties**

In no event shall Academic Journals be liable for any special, incidental, indirect, or consequential damages of any kind arising out of or in connection with the use of the articles or other material derived from the JMPPR, whether or not advised of the possibility of damage, and on any theory of liability.

This publication is provided "as is" without warranty of any kind, either expressed or implied, including, but not limited to, the implied warranties of merchantability, fitness for a particular purpose, or non-infringement. Descriptions of, or references to, products or publications does not imply endorsement of that product or publication. While every effort is made by Academic Journals to see that no inaccurate or misleading data, opinion or statements appear in this publication, they wish to make it clear that the data and opinions appearing in the articles and advertisements herein are the responsibility of the contributor or advertiser concerned. Academic Journals makes no warranty of any kind, either express or implied, regarding the quality, accuracy, availability, or validity of the data or information in this publication or of any other publication to which it may be linked.

## Research Articles

**Syphilis presenting as optic neuritis in an immunocompetent patient: Case report**

16

Franco Mónica, Colaço Luisa, Pereira Cristina, Neves Joana and Seldon Raquel

Case Report

## Syphilis presenting as optic neuritis in an immunocompetent patient: Case report

Franco Mónica\*, Colaço Luisa, Pereira Cristina, Neves Joana and Seldon Raquel

Instituto de Oftalmologia Dr. Gama Pinto, Lisboa, Portugal.

Received 14 May, 2014; Accepted 14 July, 2014

The purpose of this report was to present a case of optic neuropathy as a manifestation of secondary syphilis in an human immunodeficiency virus (HIV)-negative patient. A case of gradual loss of visual acuity in the left eye (LE) in a 53-year-old healthy woman was described. The patient present with visual acuity of 20/20 in the right eye and hand movements in the LE. Fundoscopy revealed swollen optic disc in the LE. Fluorescein angiography showed leakage of dye from the optic disc. Optical coherence tomography (OCT) confirmed the oedema in the left optic disc. Serologic testing was positive for venereal disease research laboratory (VDRL) and fluorescent treponemal antibody absorption (FTA-ABS), and negative for HIV antibodies. Ophthalmologic findings, including disc oedema, may be the presenting features of syphilis, therefore ophthalmologists have the opportunity to play a key role in the diagnosis and management of this disease, important for a good visual outcome. This study reports an infrequent case of unilateral optic neuropathy as presenting symptom of syphilis in an immunocompetent patient.

**Key words:** Syphilis, optic neuropathy, immunocompetent, penicillin.

### INTRODUCTION

Syphilis is a sexually transmitted, systemic infection caused by the spirochete bacterium *Treponema pallidum* (Lutchman et al., 2011). The incidence of syphilis continues to rise in the USA and Europe, and it is estimated that around 20% of patients with syphilis in the USA also have human immunodeficiency virus (HIV) infection (Foti et al., 2009; Ghanem, 2010; Puech et al., 2010). Ocular involvement may be silent or present as anterior uveitis, choroiditis, interstitial keratitis, retinal vasculitis, retinitis, optic neuritis, dacryoadenitis, or scleritis (Tamesis and Foster, 1990; Lukehart et al., 1988; Margo and Hamed, 1992). The observation of optic nerve abnormalities in an ophthalmological examination in a

patient with syphilis is highly suggestive of central nervous system (CNS) involvement and should be considered synonymous with neurosyphilis (Gaudio, 2006; Bandettini di Poggio et al., 2010).

The purpose of this report is to present a case of optic neuropathy as a manifestation of secondary syphilis in an HIV-negative patient.

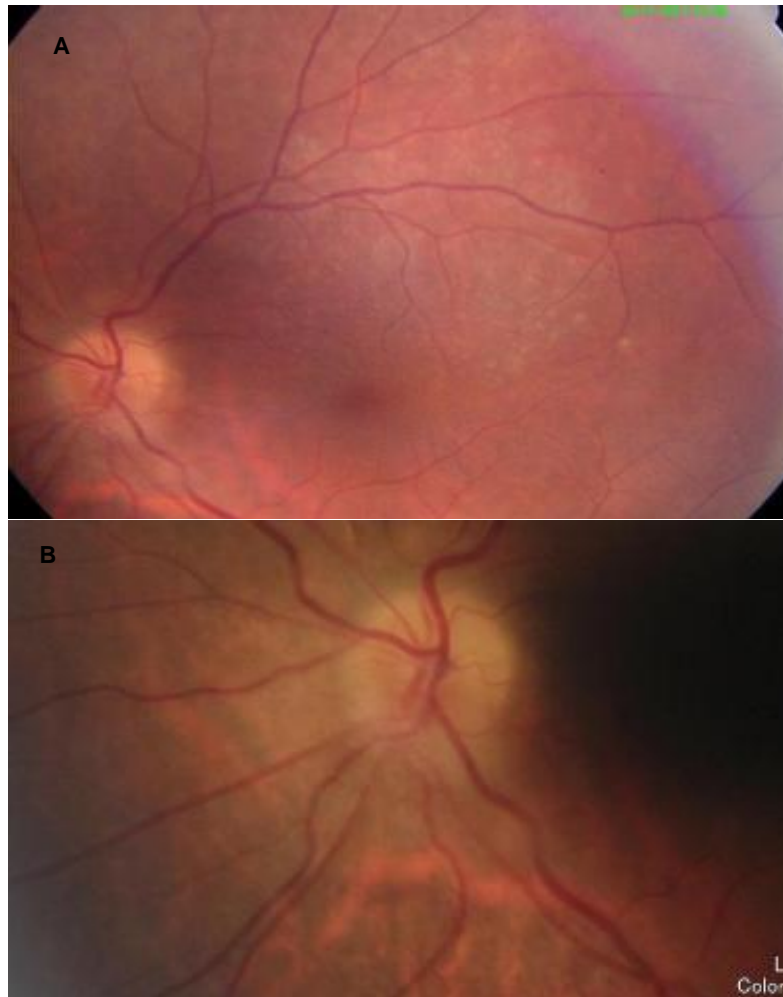
### CASE REPORT

The authors obtained written consent from the patient for the publication of her anonymised clinical data. A 53-year-

\*Corresponding author. E-mail: monicasofiafranco@gmail.com.

Author(s) agree that this article remain permanently open access under the terms of the [Creative Commons Attribution License 4.0 International License](http://creativecommons.org/licenses/by/4.0/)





**Figure 1.** Colour fundus, left eye.

old healthy woman present with complaints of decreased visual acuity in the left eye (LE) which she had begun to notice 2 weeks earlier. In a general examination, a rash on the palms and soles was detected. Best corrected visual acuity of 20/20 in the right eye (RE) and hand movements in the LE. Biomicroscopy of the anterior segment was unremarkable in both eyes, and intra-ocular pressure was 12 mmHg in both eyes. Fundoscopy showed a swollen optic disc in the LE (Figure 1), with no abnormalities detected in the RE. A left relative afferent pupillary defect was present.

Fluorescein angiography (Figure 2) showed leakage of dye from the optic disc. Optical coherence tomography (OCT) confirmed the oedema in the left optic disc (Figure 3). Serologic testing was positive for venereal disease research laboratory (VDRL, 1:128) and FTA-ABS, and negative for HIV antibodies. No abnormalities were detected during magnetic resonance imaging of the cranium and orbits. Cerebrospinal fluid (CSF) examination revealed normal opening pressure, and that CSF

protein, glucose and white cell count were within the normal range. The CSF VDRL was negative and CSF *T. pallidum* particle agglutination technique (TP.PA) was reactive at 1:160. CSF results were thus inconclusive of neurosyphilis.

The diagnosis of optic neuropathy associated with secondary syphilis in the LE was made and the patient was treated with intravenous aqueous penicillin G (four million units given every 4 h for 2 weeks). Three months after the treatment, fundoscopy revealed the absence of oedema in the LE, with a visual acuity of 20/20 in both eyes, and VDRL titre was 1:32.

## DISCUSSION

Ocular involvement in syphilis is rare and typically occurs with secondary or tertiary syphilis (Gaudio, 2006; Kiss et al., 2005; Klig, 2008). Tamesis and Foster (1990) reported that uveitis was the most common ocular manifestation

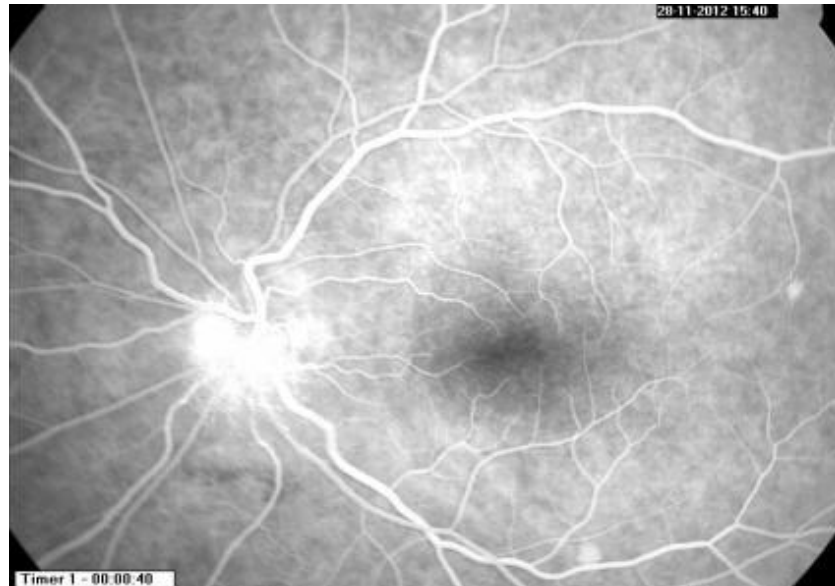


Figure 2. Fluorescein angiogram, left eye.

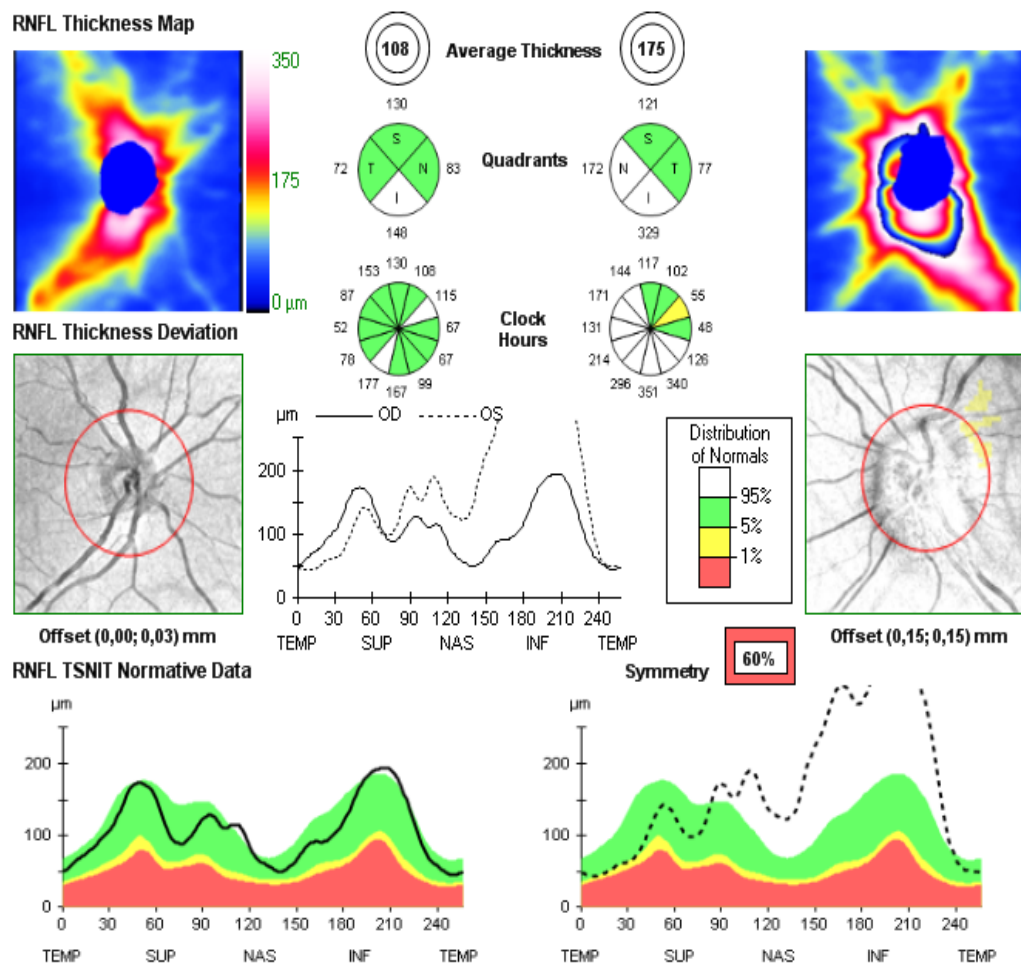


Figure 3. Optical coherence tomography optic nerve, right and left eyes.



in ocular syphilis. CNS involvement can occur at any stage of syphilis. Ocular syphilis has been reported in both immunocompromised and immunocompetent individuals (Foti et al., 2009), therefore patients should be tested for HIV (Gaudio, 2006; Barile and Flynn, 1997; Aldave et al., 2011).

The authors question the relevance of performing lumbar puncture on immunocompetent patients present with ocular manifestations who are subsequently diagnosed with syphilis, because the CSF analysis does not change the treatment regimen. Standard treatment of ocular syphilis is intravenous penicillin, as recommended for patients with neurosyphilis, regardless of immune status (Shalaby et al., 1997). There is limited data on the use of systemic corticosteroids as an adjunct for posterior uveitis, scleritis and optic neuritis associated with syphilis (Margo and Hamed, 1992).

## Conclusion

This report describes an infrequent case of unilateral optic neuropathy as presenting symptom of syphilis in an immunocompetent patient. Epidemiological data indicates a worldwide reemergence of syphilis and a high degree of suspicion is necessary in view of its multitude of presenting ocular signs without pathognomonic features. Ophthalmologic findings may be the presenting features of syphilis therefore ophthalmologists have the opportunity to play a key role in the diagnosis and management of this disease, important for a good visual outcome.

## Conflict of interest

Authors declare no conflict of interest.

## REFERENCES

- Aldave AJ, King JA, Cunningham ET Jr (2001). Ocular syphilis. *Curr. Opin. Ophthalmol.* 12(6):433-41.
- Bandettini di Poggio M, Primavera A, Capello E, Bandini F, Mazzarello G, Viscoli C, Schenone A (2010). A case of secondary syphilis presenting as optic neuritis. *Neurol. Sci.* 31(3):365-7.
- Barile GR, Flynn TE (1997). Syphilis exposure in patients with uveitis. *Ophthalmology* 104(10):1605-9.
- Foti C, Carnimeo L, Delvecchio S, Guerriero S, Cassano N, Vena GA (2009). Secondary syphilis with progressive ocular involvement in an immunocompetent patient. *Eur. J. Dermatol.* 19:288
- Gaudio PA (2006). Update on ocular syphilis. *Curr. Opin. Ophthalmol.* 17:562-566.
- Ghanem KG (2010). Evaluation and management of syphilis in the HIV-infected patient. *Curr. Infect. Dis. Rep.* 12:140-146.
- Kiss S, Damico FM, Young LH (2005). Ocular manifestations and treatment of syphilis. *Semin. Ophthalmol.* 20(3):161-7.
- Klig JE (2008). Ophthalmologic complications of systemic disease. *Emerg. Med. Clin. North Am.* 26(1):217-31.
- Lukehart SA, Hook EW, Baker-Zander SA, Collier AC, Critchlow CW, Handsfield HH (1988). Invasion of the central nervous system by *Treponema pallidum*: implications for diagnosis and treatment. *Ann. Intern. Med.* 109(11):855-62.
- Lutchman C, Weisbrod DJ, Schwartz CE (2011). Diagnosis and management of syphilis after unique ocular presentation. *Can. Fam. Physician* 57(8):896-899.
- Margo CE, Hamed LM (1992). Ocular syphilis. *Surv. Ophthalmol.* 37(3):203-20.
- Puech C, Gennai S, Pavese P, Pelloux I, Maurin M, Romanet JP, Chiquet C (2010). Ocular manifestations of syphilis: recent cases over a 2.5-year period. *Graefes Arch. Clin. Exp. Ophthalmol.* 248:1623-1629.
- Shalaby IA, Dunn JP, Semba RD, Jabs DA (1997). Syphilitic uveitis in human immunodeficiency virus-infected patients. *Arch. Ophthalmol.* 115:469-73.
- Tamesis RR, Foster CS (1990). Ocular syphilis. *Ophthalmology* 97:1281-1287.



# Medical Practice and Reviews

## Related Journals Published by Academic Journals

- *Medical Case Studies*
- *Research in Pharmaceutical Biotechnology*
- *International Journal of Obstetrics and Gynaecology Research*
- *Clinical Reviews and Opinions*
- *Journal of AIDS and HIV Research*
- *Journal of Cancer Research and Experimental Oncology*
- *Journal of Clinical Medicine and Research*
- *International Journal of Medicine and Medical*

**academicJournals**